



**PATIENT**

Percy Bowling

**PRESENTING CLINICAL SIGNS**

History: New grade II/VI heart murmur; no clinical signs. Echocardiogram prior to anesthesia for dental prophylaxis. BP: 154,157,158,160mmHg.

**SPECIES**

Feline

**ECHOCARDIOGRAM FINDINGS**

2D, m-mode, color flow and Doppler imaging is available.

**BREED**

DLH

**Left ventricle:** The LV diameter is mildly increased with adequate myocardial function. The LV wall dimensions are normal. There is mild fibrosis of the endocardium. The endocardium appears mildly remodeled. The papillary muscles appear hyperechoic and normal in dimension.

**SEX**

Male Neutered

**Left atrium:** The left atrium is mildly enlarged. No obvious thrombi seen.

**Mitral valve:** The mitral valve is normal in structure and mobility. No obvious systolic anterior motion is seen. No MR.

**AGE**

4 years

**Aortic valve/aorta:** The aortic valve is normal in morphology and mobility. Normal aortic outflow velocity; laminar flow. No aortic insufficiency.

**Right ventricle:** Normal right ventricular diameter and morphology indicating no overt evidence of pulmonary arterial hypertension.

**Right atrium:** The right atrium is mildly enlarged.

**WEIGHT**

14lbs

**Tricuspid valve:** The tricuspid valve appears normal with no tricuspid regurgitation.

**Pulmonic valve/pulmonary artery:** The pulmonic valve is normal in morphology and mobility. No pulmonic insufficiency. Normal RVOT velocity; laminar flow.

**Pericardium/other:** No pericardial or pleural effusion noted. No obvious cardiac masses.

**Heart rhythm:** ECG reveals a sinus rhythm with an average HR of 180bpm.

**INTERPRETED BY**

Maggie Machen  
Lamy, DVM  
DACVIM (Cardiology)

**2-Dimensional Measurements**

Ao diam (cm)	1.0
LA diam (cm)	1.5
LA:Ao (Swe)	1.5
IVS thickness (cm)	0.46
LVID diastole (cm)	1.8
PW thickness (cm)	0.47
LVID systole (cm)	0.8
FS (%)	57

**Doppler Measurements**

PV Vmax (m/s)	1.2
AoV Vmax (m/s)	1.4
MR Vmax (m/s)	NA
TR Vmax (m/s)	NA
TR PG (mmHg)	NA

**IMAGING**

**PERFORMED BY**

Pamela Harrigan,  
RDCS

**INTERPRETATION OF THE FINDINGS**

**HOSPITAL NAME**

Wignall Animal  
Hospital

The primary abnormality identified is mild biatrial and left ventricular enlargement. The LV wall thickness appears normal with no evidence of hypertrophy or significant remodeling at this time. These findings may suggest early unclassified cardiomyopathy (UCM) and follow up is certainly advised. Given only mild atrial dilation, the risk for complication at this time is low. No cause for the murmur is identified, making it likely physiologic in origin.

**REFERRING VET**

Dr. Colella

Prognosis is guarded until progression is assessed. No obvious indication for medications at this time. Patient may be at risk for progression to CHF, development of blood clots and/or malignant arrhythmias in the future.

**INVOICE**

23818

**DATE**

4/21/22



**PATIENT**

Percy Bowling

**SPECIES**

Feline

**BREED**

DLH

**SEX**

Male Neutered

**AGE**

4 years

**WEIGHT**

14lbs

**INTERPRETED BY**

Maggie Machen  
 Lamy, DVM  
 DACVIM (Cardiology)

**IMAGING PERFORMED BY**

Pamela Harrigan,  
 RDCS

**HOSPITAL NAME**

Wignall Animal  
 Hospital

**REFERRING VET**

Dr. Colella

**INVOICE**

23818

**DATE**

4/21/22

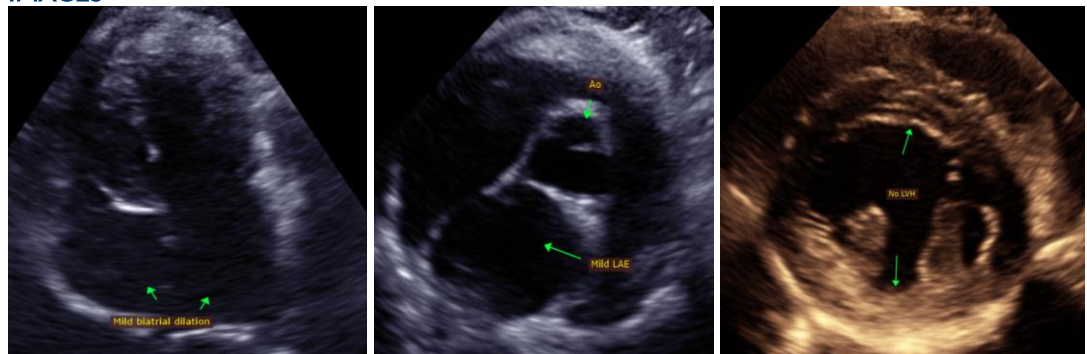
**RECOMMENDATIONS**

- Given these findings, no medications are indicated.
- Anesthetic risk is considered mild, however judicious IV fluid rates are advised to avoid fluid overload. Additionally, drugs that stimulate heart rate should be avoided unless clinically necessary (glycopyrrolate, atropine). Avoid vasodilators as this may worsen the obstruction. A reasonable protocol includes opioid/benzodiazepine premedication, propofol induction, isoflurane maintenance. Additionally, steroids should be used with caution on older cats, as even a 'normal' geriatric heart can develop evidence of intolerance and fluid retention.
- Monitor at home for signs of cardiac compromise, including respiratory changes and/or signs of a blood clot event (paralysis, neurologic changes).

**PLAN**

- Recommend recheck echocardiogram in 6months to screen for progression.

**IMAGES**



The information and recommendations provided are based on the images presented by the referring veterinarian. No evaluation can be communicated regarding pathology that was not visible in the image/video clips provided.

Thank you for this referral. This report was generated using transcription software, and minor dictation errors may be present. If the clinical or image interpretation does not parallel your findings or if I can be of any further assistance, please contact me.

**Maggie Machen Lamy, DVM**  
 Diplomate of the American College of Veterinary Internal Medicine (Cardiology)  
 info@sonopath.com